

Post-Intubation Tracheal Tear in Myomectomy Patient

About A*

Department of Consultant Regional and cardiothoracic anesthesia, Switzerland

ISSN: 2578-0379



***Corresponding author:** Aboud A, Department of Consultant Regional and Cardiothoracic Anesthesia, Switzerland

Submission:  June 28, 2021

Published:  October 06, 2021

Volume 4 - Issue 4

How to cite this article: Aboud A. Post-Intubation Tracheal Tear in Myomectomy Patient. *Surg Med Open Acc J.* 4(4). SMOAJ.000591. 2021. DOI: [10.31031/SMOAJ.2021.04.000591](https://doi.org/10.31031/SMOAJ.2021.04.000591)

Copyright@ Aboud A, This article is distributed under the terms of the Creative Commons Attribution 4.0 International License, which permits unrestricted use and redistribution provided that the original author and source are credited.

Abstract

Twelve hours after extubating, a 33-year-old woman developed extensive Subcutaneous (surgical) emphysema, involving the neck, and upper chest Extending from skull base down to the mediastinum left sided Pneumomediastinum and pneumothorax, was confirmed by neck and chest CT-scan. The location of the lesion and features of the patient favored conservative Treatment with antibiotic cover. The patient made a full and uncomplicated Recovery and was discharged ten days after the original injury.

Keywords: Anesthesia; Intubation; Myomectomy; Trachea; Tear

Introduction

Tracheal tear is a rare and life-threatening complication, that usually occur after blunt trauma to the chest, but which may complicate tracheal Intubation. We report this rare case of post-intubation tracheal tear after abdominal Myomectomy under general anesthesia.

Case report

A 33-year-old woman was scheduled for abdominal myomectomy under general anesthesia. After induction of anesthesia with propofol 150mg, fentanyl 150mcg and rocuronium 40mg, oral intubation was performed without any difficulty (Cormack lehane view 1) using a 7.5 cuffed preformed orotracheal tube without stylet. The cuff was inflated with 7ml of air and continuously monitored to sustain the pressure during the procedure. Anesthesia was maintained with isoflurane. The entire surgery lasted approximately 60min.

Six hours after extubating the patient started to complain of shortness of breath and chest discomfort. Consequently, ECG showed: Normal sinus rhythm, no significant changes, ABGS "on room air": PO₂ 80mmHg and 90% O₂ sat. She responded positively as 96% improved on O₂ face mask and no shortness of breath anymore.

Twelve hours after extubating, the anesthesiologist attended because the patient had suddenly developed subcutaneous emphysema of the facial, bilateral later cervical and upper anterior chest, although she did not complain of chest pain or dyspnea. In addition, the chest X-ray did not present any abnormal signs.

The results of the arterial blood gas on room air were pH=7.35 PCO₂=43mmHg, PO₂=68mmHg HCO₃⁻ = 22mmHg and SpO₂=92%. A thoracic Computed Tomography (CT) showed: Extensive subcutaneous (surgical) emphysema, involving the neck (Figure 1), and upper chest (Figure 2), extending from skull base down to the mediastinum (Figure 1), moderate left sided pneumomediastinum and pneumothorax, defect 40×10mm is seen in the posterior (membranous) portion of dorsal trachea from the +1-D3.

Traumatic Tracheal tear was suspected, and the patient was transferred to surgical ICU. Then a chest tube was inserted while the patient kept on simple face mask with daily ABGs. According to the location and the features of the lesion, the conservative treatment with antibiotic cover (cephalosporin and aminoglycoside) and monitoring in the intensive care unit were the ideal treatment plan. Mechanical ventilation, bilateral endobronchial intubation and surgery were available if necessary.

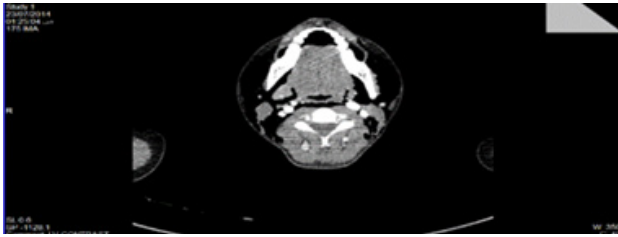


Figure 1: Thoracic CT showing diffuse soft tissues emphysema of the neck and skull base.

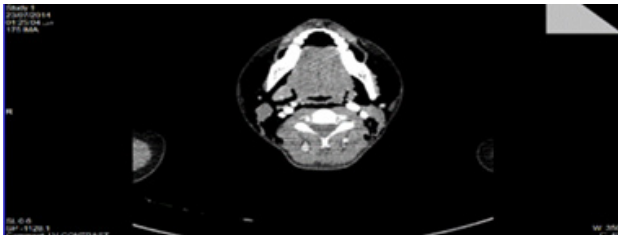


Figure 2: Thoracic CT showing diffuse soft tissues emphysema of the upper chest.

The patient improved, and five days later, the chest CT showed that the left tube is seen with almost complete resolution of left pneumothorax, and the surgical emphysema appears smaller in size at tracheal tear. There are no significant changes seen neither a fistula was noted. After three more days in a general medical ward, the patient was discharged home in good condition, ten days after the initial injury. One month later, the patient was scheduled to come back to surgical clinic for reevaluation; she was presented with good general condition.

Discussion

Tracheal tear following intubation is a rare complication [1]. Risk factors for this complication may be related to the patient, the anesthesiologist, the endotracheal tube size, and the technique of intubation [1,2]. Often, the cause is multifactorial [1]. Although, in some cases, the main cause may remain iatrogenic [1]. Patient risk factors include conditions affecting tracheal anatomy as the trachea is more vulnerable in female, advanced age, short stature, chronic obstructive pulmonary disease and corticosteroid therapy [2]. The assumption that a membranous trachea is fewer firms in women than in men [2].

There are multiple factors that contribute to the technique of intubation, which may be related to mechanical factors as trauma during intubation, or over inflation of the cuff, coughing etc., and size of the tube [3-5]. Although, over inflation of endotracheal cuff and sudden manipulation of the tube are two commonest reasons but direct tear caused by the tube itself is extremely rare [6].

Multiple intubations attempt in difficult cases could result tracheal laceration. Nevertheless, the operators involved are well-trained anesthesiologists and the intubations were reported as easy and uneventful as in our case. Other causes of iatrogenic tracheal laceration are the use of a stylet inside the tube while the stylet not being removed as soon as the tube tip passed the vocal cords, or the use of a double-lumen tube with direct trauma of the tip or

the carina [2]. We can differentiate this depending on the level of the tear, at cervical level (when using a single-lumen tube as in our case) or at thoracic level (when using a double-lumen tube), may indicate a cuff-induced rupture [2].

Finally, cuff over-inflation acts as a distension force and is reported as cause in some cases [1]. Using nitrous oxide tends to expand more the cuff, so monitoring cuff pressure during surgery is recommended and essential. The possible explanation in our case report is most probably due to large endotracheal tube and to lesser extent the amount of air inflation in cuff. The clinical manifestations of tracheal tear are subcutaneous emphysema, pneumothorax, hemoptysis and respiratory failure [1]. Usually, they appear during surgery or immediately in postoperative period [2]. Sometimes it may delay hours later as in our case report.

Chest X-ray and chest CT can show soft tissues emphysema, pneumomediastinum, pneumopericardium and/or pneumothorax [2,4]. An emergency bronchoscope is necessary to confirm the diagnosis and to determine the extension of the laceration [1,2,5]. Regarding treatment strategy of a post-intubation tracheal tear depends on the size and the location of the rupture, clinical presentation, and the condition of the patient [1].

Two therapeutic strategies are proposed: a surgical or non-surgical approach [3]. The current tendency is to decrease invasive surgical treatment for the benefit of conservative management [1,3] Surgical repair is the preferred when a transmural tear with a 2cm length causing pneumothorax and/or pneumo-mediastinum and if the lesion is at thoracic level.

Conservative treatment could be an alternative in some patients if: small lacerations in the upper third of the trachea, without full thickness of the tracheal wall, no gross air leak and patients who are breathing spontaneously without any compromise [6]. Conservative treatment in large complete tracheal rupture in old age with critical general condition could be an option [3]. Other treatment can include mechanical ventilation after tracheal or bilateral endobronchial intubation (with the cuff inflated distal to the tear as in our case), chest drain, continuous airway humidification, broad-spectrum antibiotics, and regular chest physiotherapy [3].

Good healing and the absence of stenosis could be verified with tracheal fiber endoscopy one month after the initial injury [3]. Our case report shows the effectiveness of the conservative therapeutic strategy of a large tracheal injury. Selection of treatment for post-intubation tracheal tear must be individualized. Airway management is a fundamental aspect of anesthetic practice, and it is essential for anesthesiologists to be vigilant to these complications, and to have an effective strategy to prevent and manage these complications when they happen.

References

1. Carbognani P, Bobbio A, Cattelani L, Internullo E, Caporale D, et al. (2004) Management of postintubation membranous tracheal rupture. *Ann Thorac Surg* 77(2): 406-409.
2. Ané MCH, Picard E, Jonquet O, Mary H (1995) Membranous tracheal rupture after endotracheal intubation. *Ann Thorac Surg* 60(5): 1367-1371.

3. Jougon J, Ballester M, Choukroun E, Dubrez J, Reboul G, et al. (2000) Conservative treatment for postintubation tracheobronchial rupture. *Ann Thorac Surg* 69(1): 216-220.
4. Gries CJ, Pierson DJ (2007) Tracheal rupture resulting in life-threatening subcutaneous emphysema. *Respir Care* 52(2): 191-195.
5. Eipe N, Choudhrie A (2007) Tracheal rupture in a child with blunt chest injury. *Pediatric Anesthesia* 17(3): 273-277.
6. Beiderlinden M, Adamzik M, Peters J (2005) Conservative treatment of tracheal injuries. *Anesth Analg* 100(1): 210-214.

For possible submissions Click below:

[Submit Article](#)